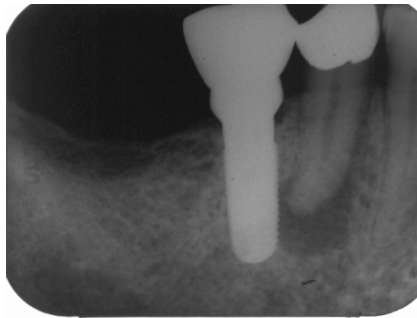
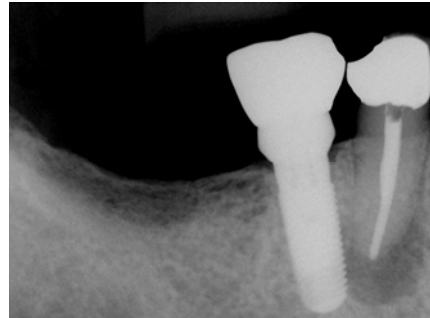


Resilon Healing Case

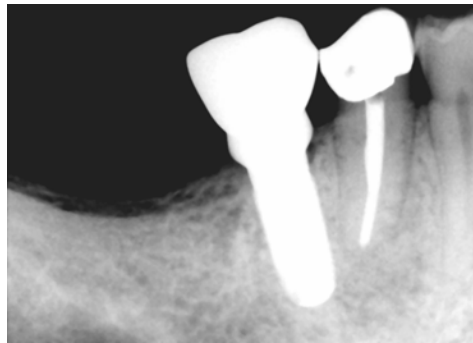
by: Dr. Randall T. Hedrick, DDS
Diplomate, ABE



2/20/06



3/8/06



This case was referred to my office to see if tooth #29 could be treated before the adjacent implant was adversely affected. Diagnostic testing revealed that tooth #29 had pulpal necrosis with chronic apical periodontitis. After access was performed pus exuded from the canal filling the pulp chamber. The canal was prepared to an apical diameter of #70 with LightSpeed LSX. 15% EDTA and 6% NaOCl were used as irrigants. Drainage continued and the canal was medicated with $\text{Ca}(\text{OH})_2$ and the access was closed. After 8 days the patient returned, the medication was removed and the apical preparation was increased to a final apical diameter of #80 LSX. Irrigation with 6% NaOCl, 15% EDTA, and distilled water was completed in that order. The canal was dried, primed, and Epiphany[®] sealer was placed into the canal with a paper point. A Resilon Simplifil apical plug was coated with sealer and seated in the apex. The metal carrier was removed and the coronal part of the Simplifil plug was compacted with a 5/7 plugger. The canal was backfilled with heated Resilon from an Obtura pellet gun and condensed with a 5/7 plugger. The plugger void was filled with another Obtura injection. The access was temporized and later restored by the patient's dentist. When the patient returned at 8 months the lesion had healed completely. There were no signs or symptoms. Success in this case was due to the biologically optimal canal preparation and disinfection as well as the excellent seal provided by the Resilon/Epiphany obturation.

Randall T. Hedrick, DDS
Diplomate, ABE

Ps: This case may also have some merit in combating the tendency of oral surgeons to blame implant failures on adjacent endodontically treated teeth.